



Wound Management in Prolong Steroid Used with Poor Skin Integrity

Sorayaphan Boonton¹ , Ruenkaew Changkittirat¹ , Saroya Hwangcharoen¹

¹ Siriraj Hospital, Mahidol University, Thailand

Background

Long term high dose steroid usage effect to decrease and flattening keratinocyte cell. Among proliferation phase was disturbed by reducing collagen and ground substance. Besides due to sodium and fluid retention, therefore whole body was swelling. Cause poor skin integrity and delayed wound healing.

Introduction

A 12 years old girl was diagnosed IgA Nephropathy treated by high dose steroid usage almost a year. She had dyspnea from volume over load leading to inactivity. We found striae, bleb, purpura and abrasion scattering all of her body. She was suffered from painful and discomfort.

Methods

The goals of treatment are preventing new skin breakdown and infection, improving wound healing. Before starting intervention we reduce patient painful by medicine for pain killer.

1. Removed old dressing gently with adhesive remover.
2. Cleaned with normal saline on skin breakdown and skin cleanser cream on intact skin.
3. Protected surrounding skin with skin barrier cream.
4. Applied soft silicone polyurethane foam for protect skin breakdown on intact skin. (Figure 1)
5. Applied antimicrobial polyurethane foam on skin breakdown area to protect infection. (Figure 1)

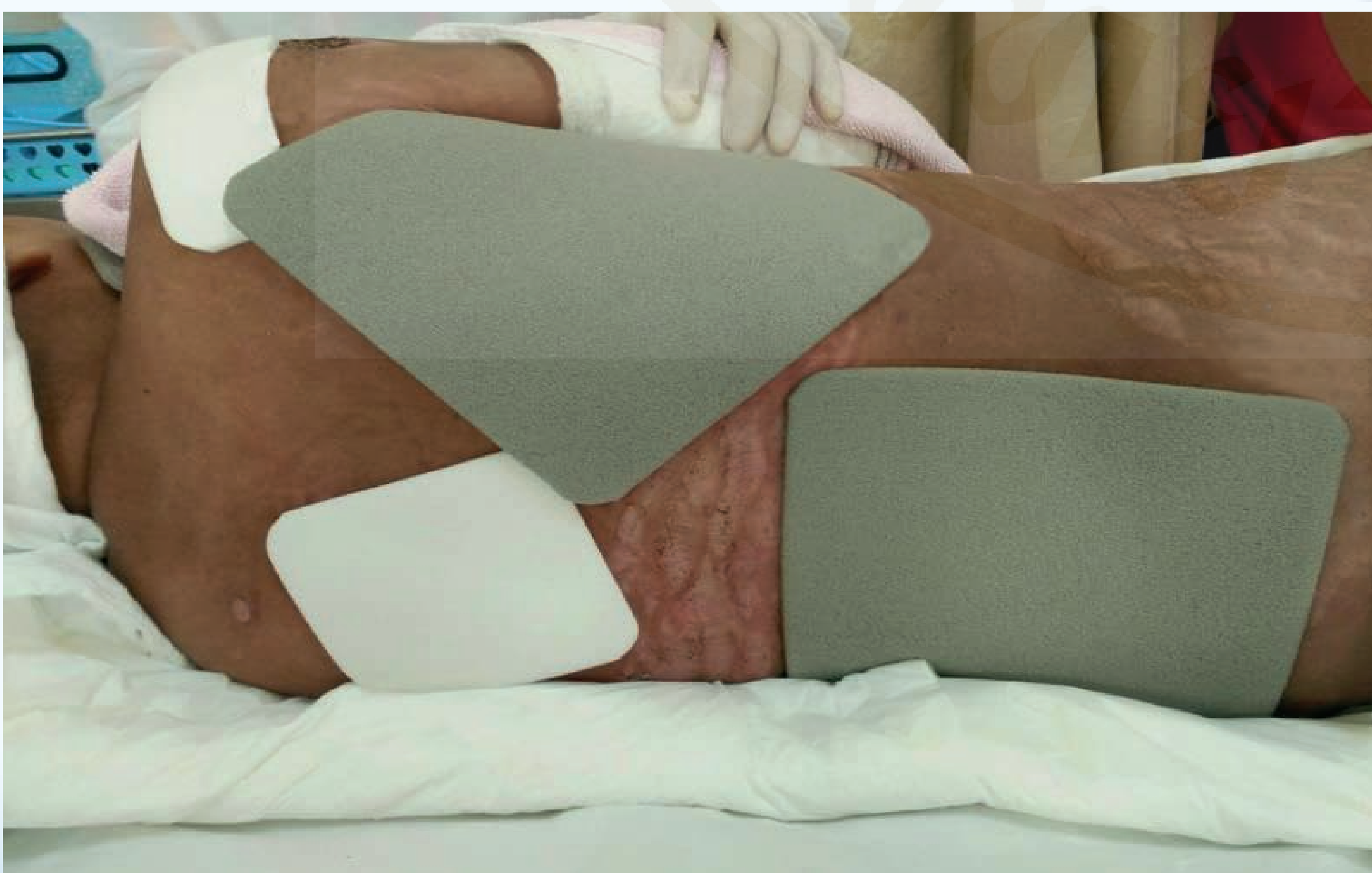


Figure 1 Proper management for different type of skin

In addition, we collaborated with multidisciplinary team for holistic care and cover all her conditions. After the meeting physician commit to change treatment from corticosteroid to immunosuppressive medication. And support nutrition by mineral supplement.

Results

3 months after changing medication treatment and wound management. All lesions was improved and good skin integrity. (Figure 2)

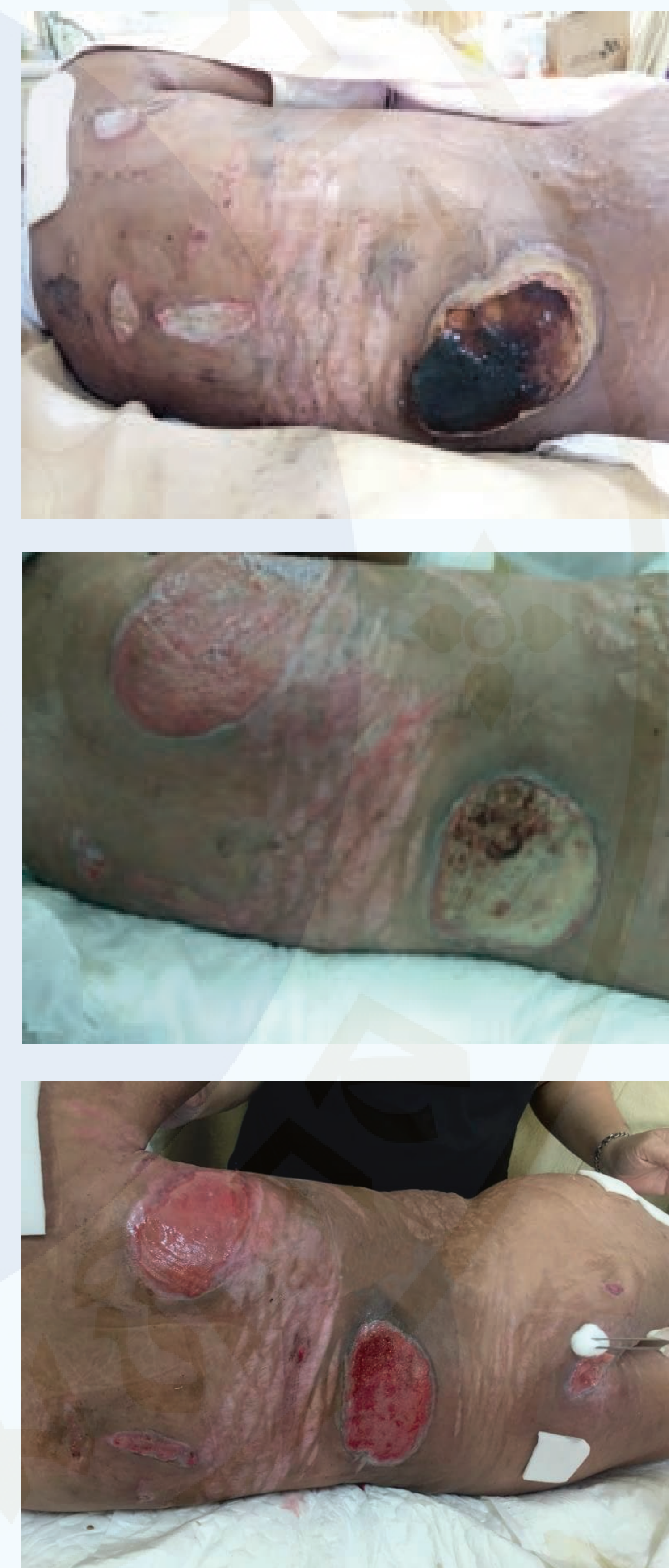

Figure 2 Wound Progression

Conclusion

The key success to management skin integrity is reasonable wound products selection and appropriate treatment. The team collaboration is important for wound management in prolong steroid used.

Reference

- Coondoo, A., Phiske, M., Verma, S., & Lahiri, K. (2014). Side-effects of topical steroids: A long overdue revisit. Indian Dermatology Online Journal, 5(4), 416-416.



Wound Management in Prolong Steroid Used with Poor Skin Integrity

Sorayaphan Boonton¹ , Ruenkaew Changkittirat¹ , Saroya Hwangcharoen¹

¹ Siriraj Hospital, Mahidol University, Thailand

Background

Long term high dose steroid usage effect to decrease and flattening keratinocyte cell. Among proliferation phase was disturbed by reducing collagen and ground substance. Besides due to sodium and fluid retention, therefore whole body was swelling. Cause poor skin integrity and delayed wound healing.

Introduction

A 12 years old girl was diagnosed IgA Nephropathy treated by high dose steroid usage almost a year. She had dyspnea from volume over load leading to inactivity. We found striae, bleb, purpura and abrasion scattering all of her body. She was suffered from painful and discomfort.

Methods

The goals of treatment are preventing new skin breakdown and infection, improving wound healing. Before starting intervention we reduce patient painful by medicine for pain killer.

1. Removed old dressing gently with adhesive remover.
2. Cleaned with normal saline on skin breakdown and skin cleanser cream on intact skin.
3. Protected surrounding skin with skin barrier cream.
4. Applied soft silicone polyurethane foam for protect skin breakdown on intact skin. (Figure 1)
5. Applied antimicrobial polyurethane foam on skin breakdown area to protect infection. (Figure 1)

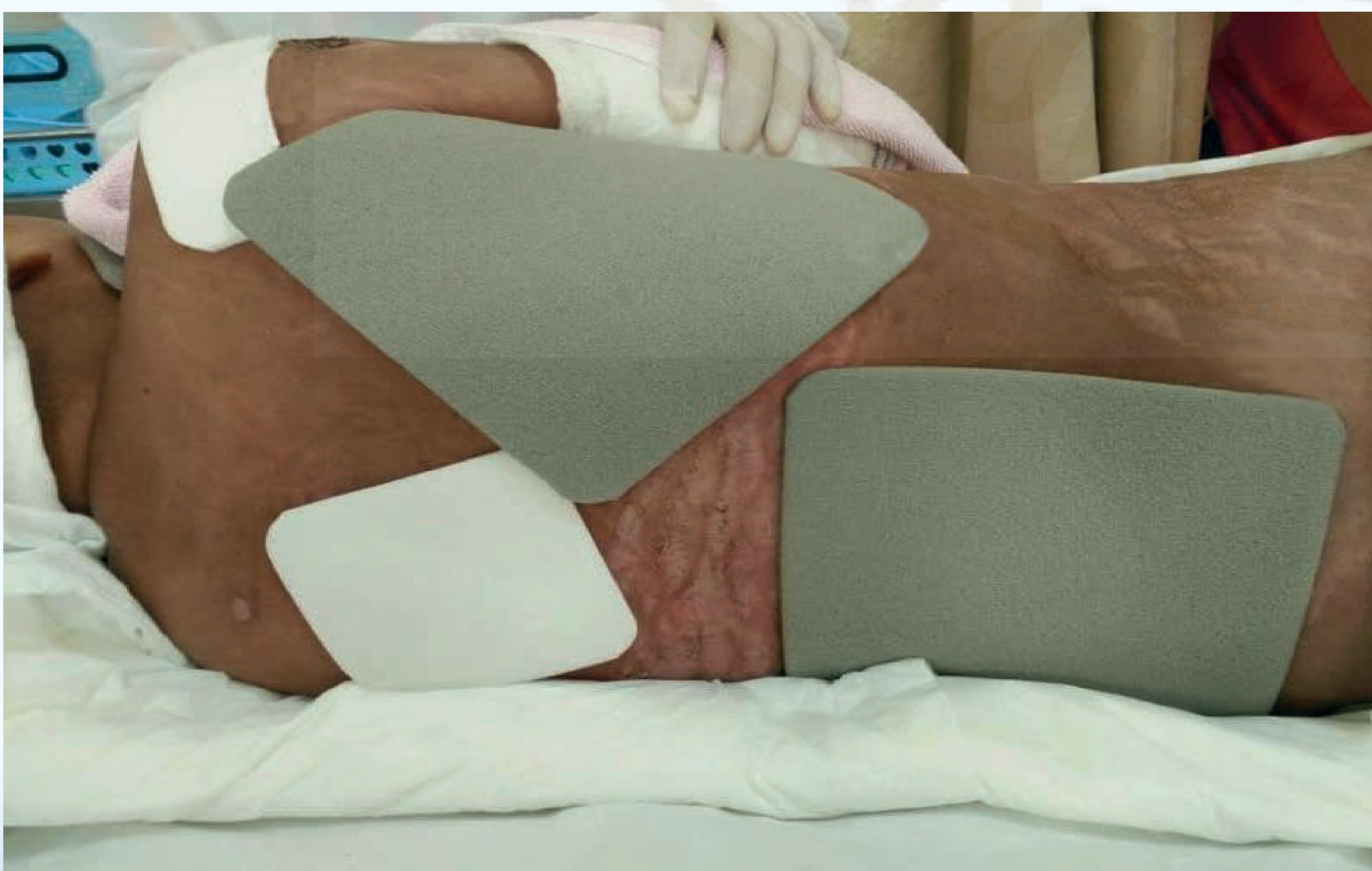


Figure 1 Proper management for different type of skin

In addition, we collaborated with multidisciplinary team for holistic care and cover all her conditions. After the meeting physician commit to change treatment from corticosteroid to immunosuppressive medication. And support nutrition by mineral supplement.

Results

3 months after changing medication treatment and wound management. All lesions was improved and good skin integrity. (Figure 2)

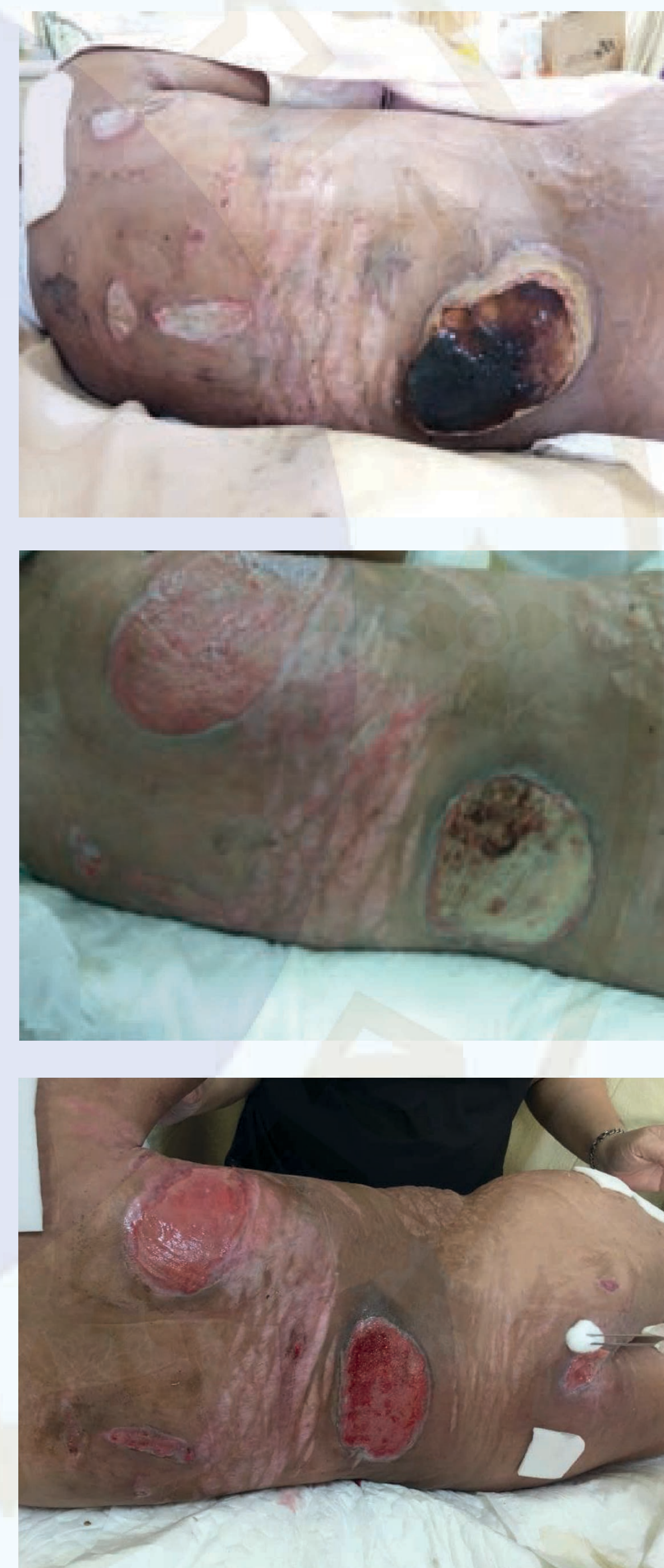

Figure 2 Wound Progression

Conclusion

The key success to management skin integrity is reasonable wound products selection and appropriate treatment. The team collaboration is important for wound management in prolong steroid used.

Reference

- Coondoo, A., Phiske, M., Verma, S., & Lahiri, K. (2014). Side-effects of topical steroids: A long overdue revisit. Indian Dermatology Online Journal, 5(4), 416-416.



Wound Management in Prolong Steroid Used with Poor Skin Integrity

Sorayaphan Boonton¹ , Ruenkaew Changkittirat¹ , Saroya Hwangcharoen¹

¹ Siriraj Hospital, Mahidol University, Thailand

Background

Long term high dose steroid usage effect to decrease and flattening keratinocyte cell. Among proliferation phase was disturbed by reducing collagen and ground substance. Besides due to sodium and fluid retention, therefore whole body was swelling. Cause poor skin integrity and delayed wound healing.

Introduction

A 12 years old girl was diagnosed IgA Nephropathy treated by high dose steroid usage almost a year. She had dyspnea from volume over load leading to inactivity. We found striae, bleb, purpura and abrasion scattering all of her body. She was suffered from painful and discomfort.

Methods

The goals of treatment are preventing new skin breakdown and infection, improving wound healing. Before starting intervention we reduce patient painful by medicine for pain killer.

1. Removed old dressing gently with adhesive remover.
2. Cleaned with normal saline on skin breakdown and skin cleanser cream on intact skin.
3. Protected surrounding skin with skin barrier cream.
4. Applied soft silicone polyurethane foam for protect skin breakdown on intact skin. (Figure 1)
5. Applied antimicrobial polyurethane foam on skin breakdown area to protect infection. (Figure 1)

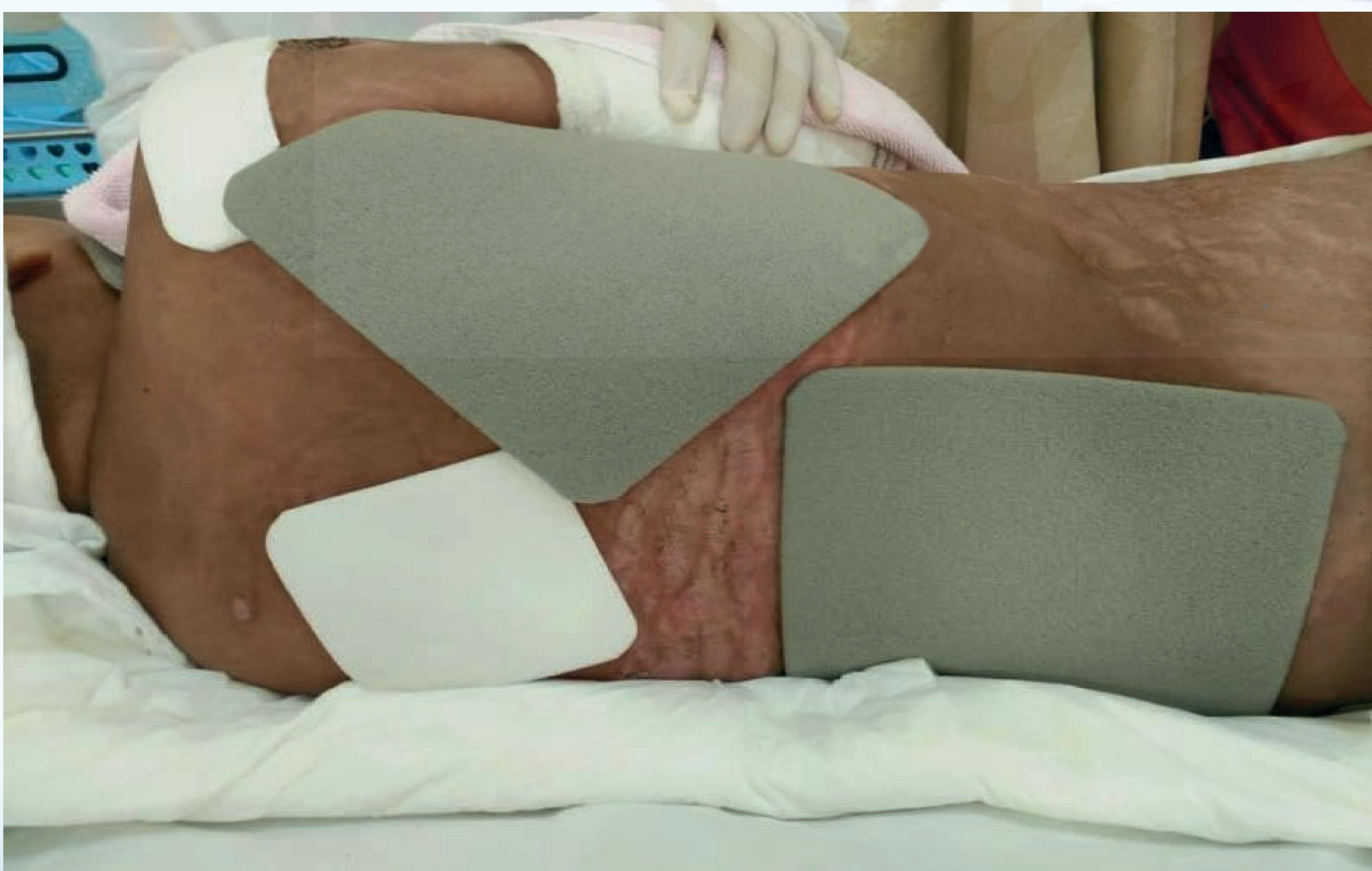


Figure 1 Proper management for different type of skin

In addition, we collaborated with multidisciplinary team for holistic care and cover all her conditions. After the meeting physician commit to change treatment from corticosteroid to immunosuppressive medication. And support nutrition by mineral supplement.

Results

3 months after changing medication treatment and wound management. All lesions was improved and good skin integrity. (Figure 2)

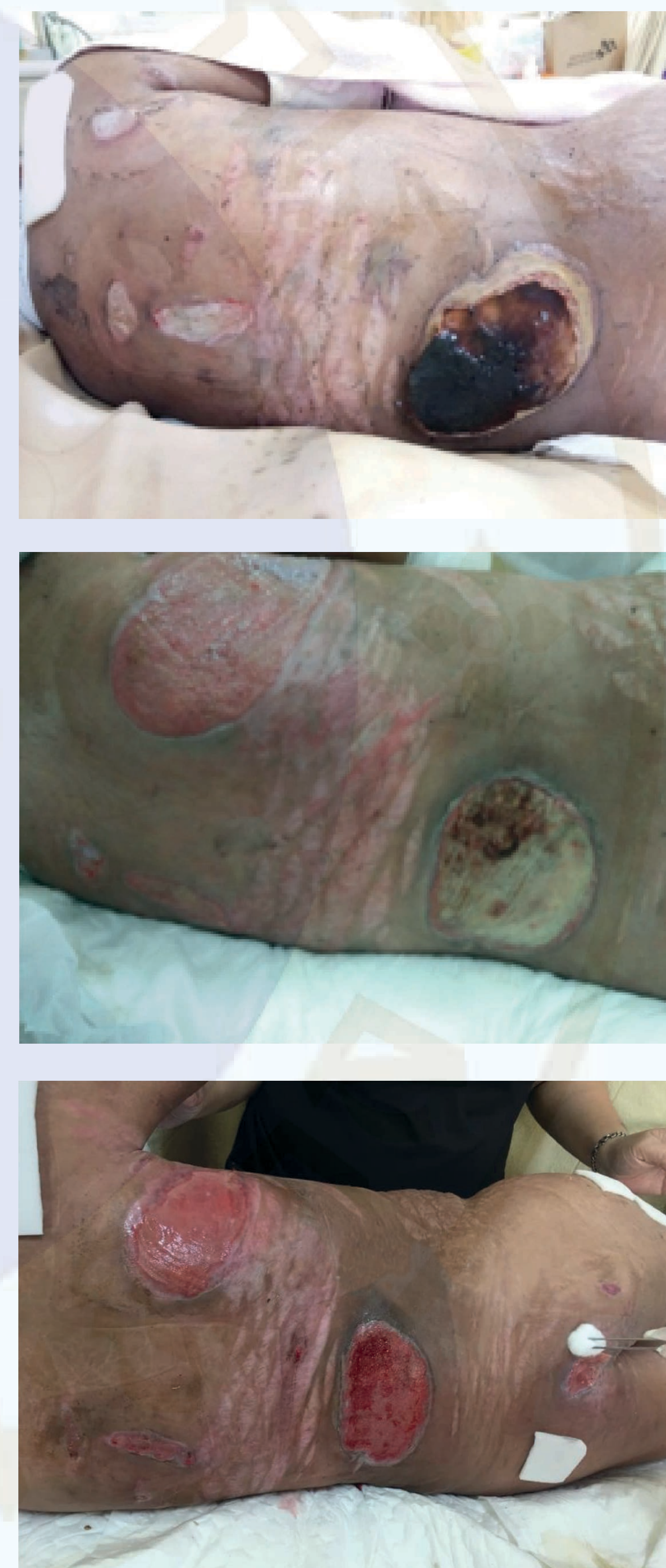

Figure 2 Wound Progression

Conclusion

The key success to management skin integrity is reasonable wound products selection and appropriate treatment. The team collaboration is important for wound management in prolong steroid used.

Reference

- Coondoo, A., Phiske, M., Verma, S., & Lahiri, K. (2014). Side-effects of topical steroids: A long overdue revisit. Indian Dermatology Online Journal, 5(4), 416-416.



Wound Management in Prolong Steroid Used with Poor Skin Integrity

Sorayaphan Boonton¹ , Ruenkaew Changkittirat¹ , Saroya Hwangcharoen¹

¹ Siriraj Hospital, Mahidol University, Thailand

Background

Long term high dose steroid usage effect to decrease and flattening keratinocyte cell. Among proliferation phase was disturbed by reducing collagen and ground substance. Besides due to sodium and fluid retention, therefore whole body was swelling. Cause poor skin integrity and delayed wound healing.

Introduction

A 12 years old girl was diagnosed IgA Nephropathy treated by high dose steroid usage almost a year. She had dyspnea from volume over load leading to inactivity. We found striae, bleb, purpura and abrasion scattering all of her body. She was suffered from painful and discomfort.

Methods

The goals of treatment are preventing new skin breakdown and infection, improving wound healing. Before starting intervention we reduce patient painful by medicine for pain killer.

1. Removed old dressing gently with adhesive remover.
2. Cleaned with normal saline on skin breakdown and skin cleanser cream on intact skin.
3. Protected surrounding skin with skin barrier cream.
4. Applied soft silicone polyurethane foam for protect skin breakdown on intact skin. (Figure 1)
5. Applied antimicrobial polyurethane foam on skin breakdown area to protect infection. (Figure 1)

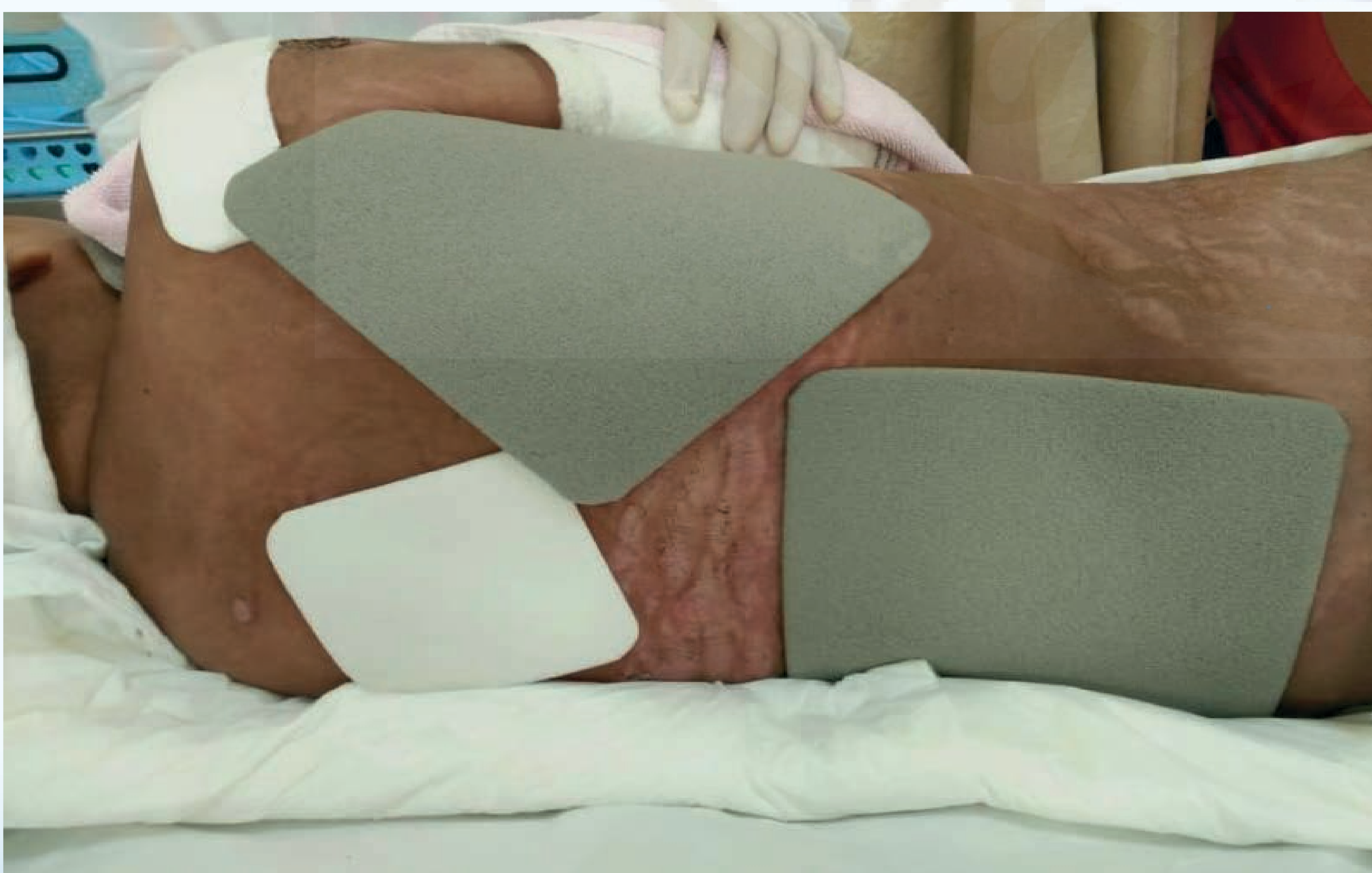


Figure 1 Proper management for different type of skin

In addition, we collaborated with multidisciplinary team for holistic care and cover all her conditions. After the meeting physician commit to change treatment from corticosteroid to immunosuppressive medication. And support nutrition by mineral supplement.

Results

3 months after changing medication treatment and wound management. All lesions was improved and good skin integrity. (Figure 2)

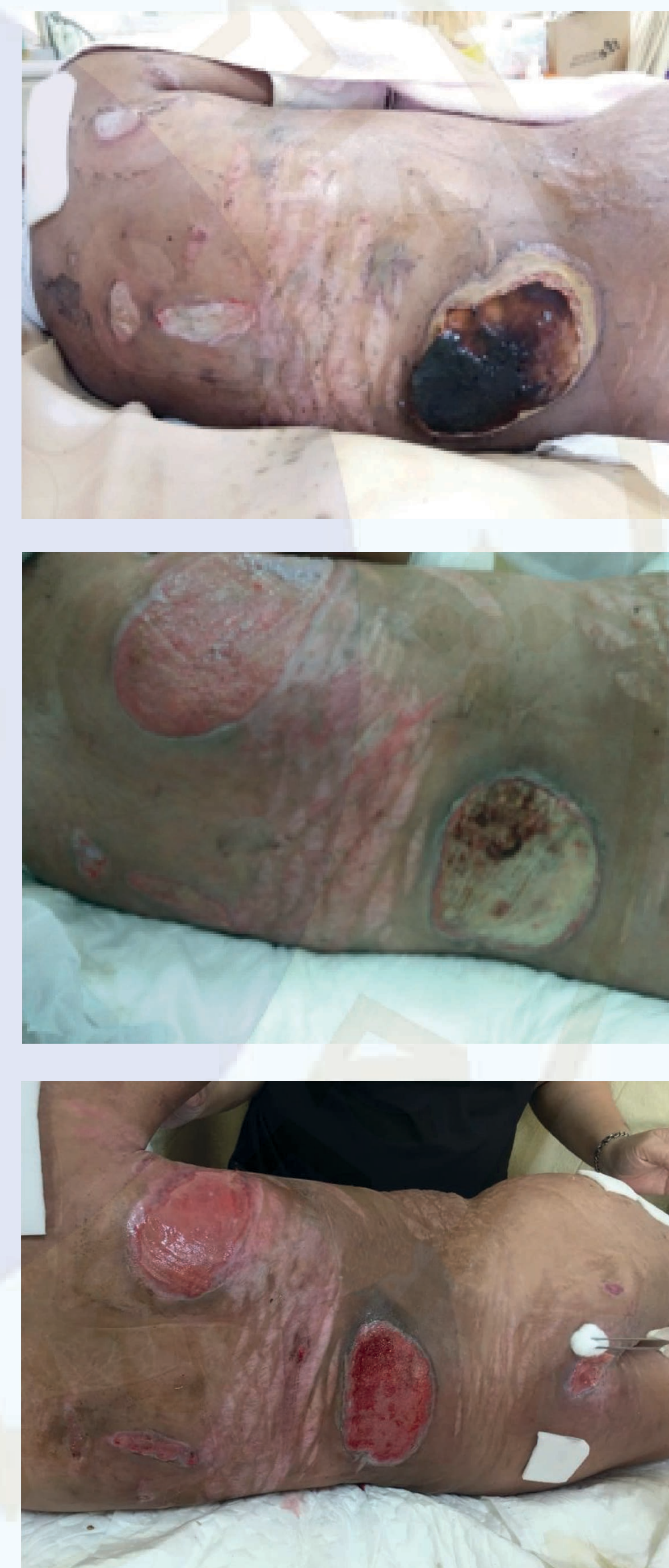

Figure 2 Wound Progression

Conclusion

The key success to management skin integrity is reasonable wound products selection and appropriate treatment. The team collaboration is important for wound management in prolong steroid used.

Reference

- Coondoo, A., Phiske, M., Verma, S., & Lahiri, K. (2014). Side-effects of topical steroids: A long overdue revisit. Indian Dermatology Online Journal, 5(4), 416-416.