



Complexity management in Abdominal wound Dehiscence and Enteroatmospheric fistula



Namtip Wongsaroj¹, Supanida Chaichit¹, Vimalux Chaisakchatree¹

¹Siriraj Hospital, Mahidol University, Thailand

Background

Wound dehiscence is mechanical failure of wound healing and when combine with Enteroatmospheric have a lot of effluent, skin separation, painful, peristomal skin lesion. There are challenging to find management. Their etiology is complex and range from persistent abdominal infection and the problematic become the effluent drain directly onto dehiscence wound failure to control although foley's catheter or nasogastric tube and pouching are applied to isolation of effluent from the wound bed to promote wound healing and assisted in dressing adherence. But it had to be changed or repair multiple time per day. The leakage of effluent at basement of pouching lead to skin irritation and wound not healed.

Caes report

A 36-year male. Dr.Recurrent CA Lower Restum with Caruinomatosis Peritonei SIP APR, CMT& RT. The post Operative developed infection dehiscence wound was yellow slough 3x14.5 cm. EAF was located in wound

Intervention

1. Applied skin protectant polymeric cyanoacrylate solution all intact and damaged skin area (figure 1)
2. Applied primary dressing with hydrofiber Ag, secondary dressing with hydrocolloid (figure 2)
3. Separated fistula from wound by pouching procedure with one piece drainable transparent pouch.(figure 3)

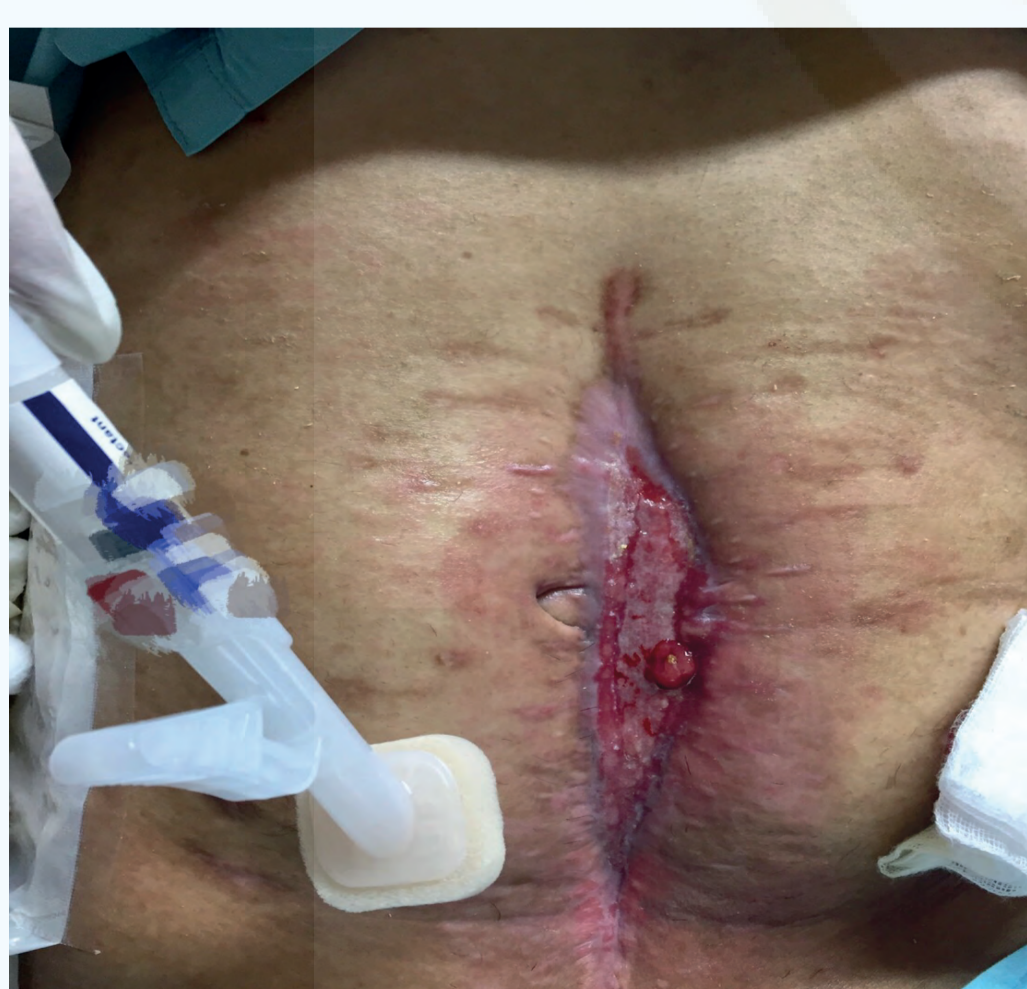

figure 1

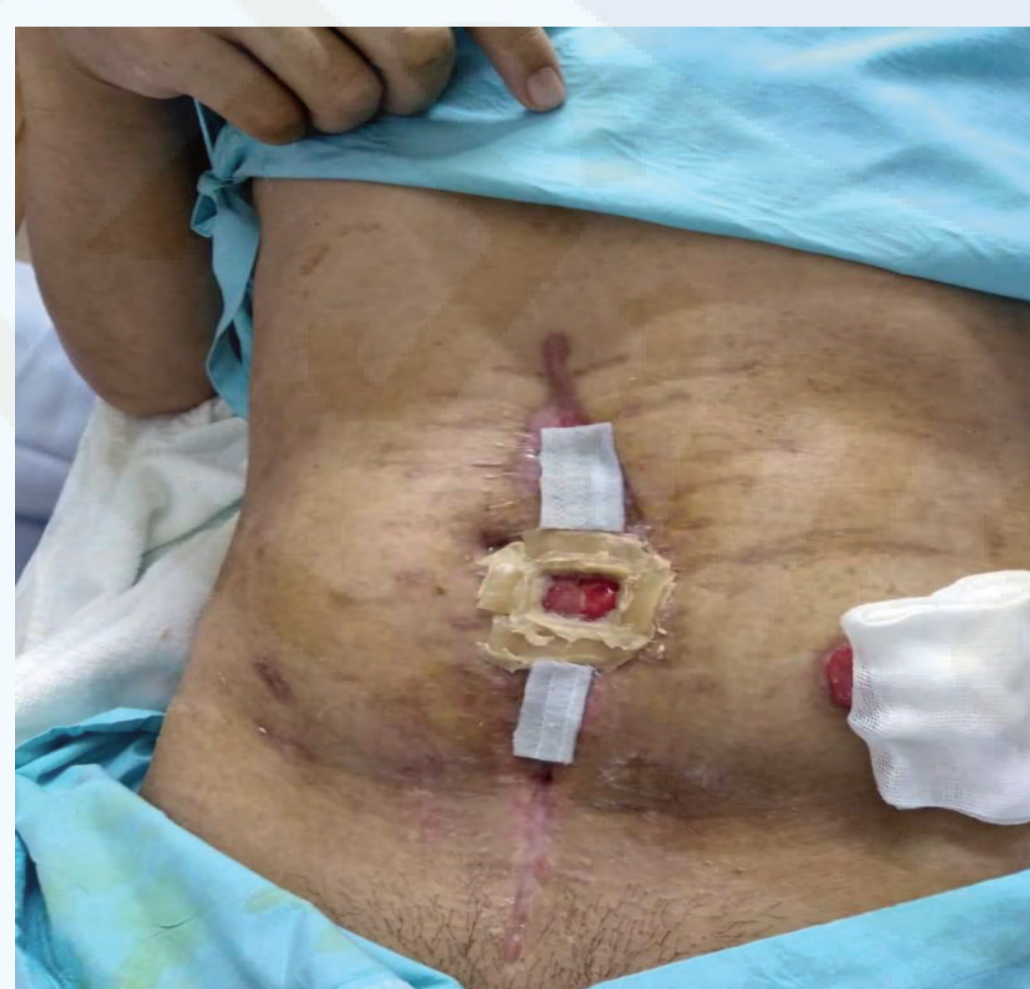

figure 2

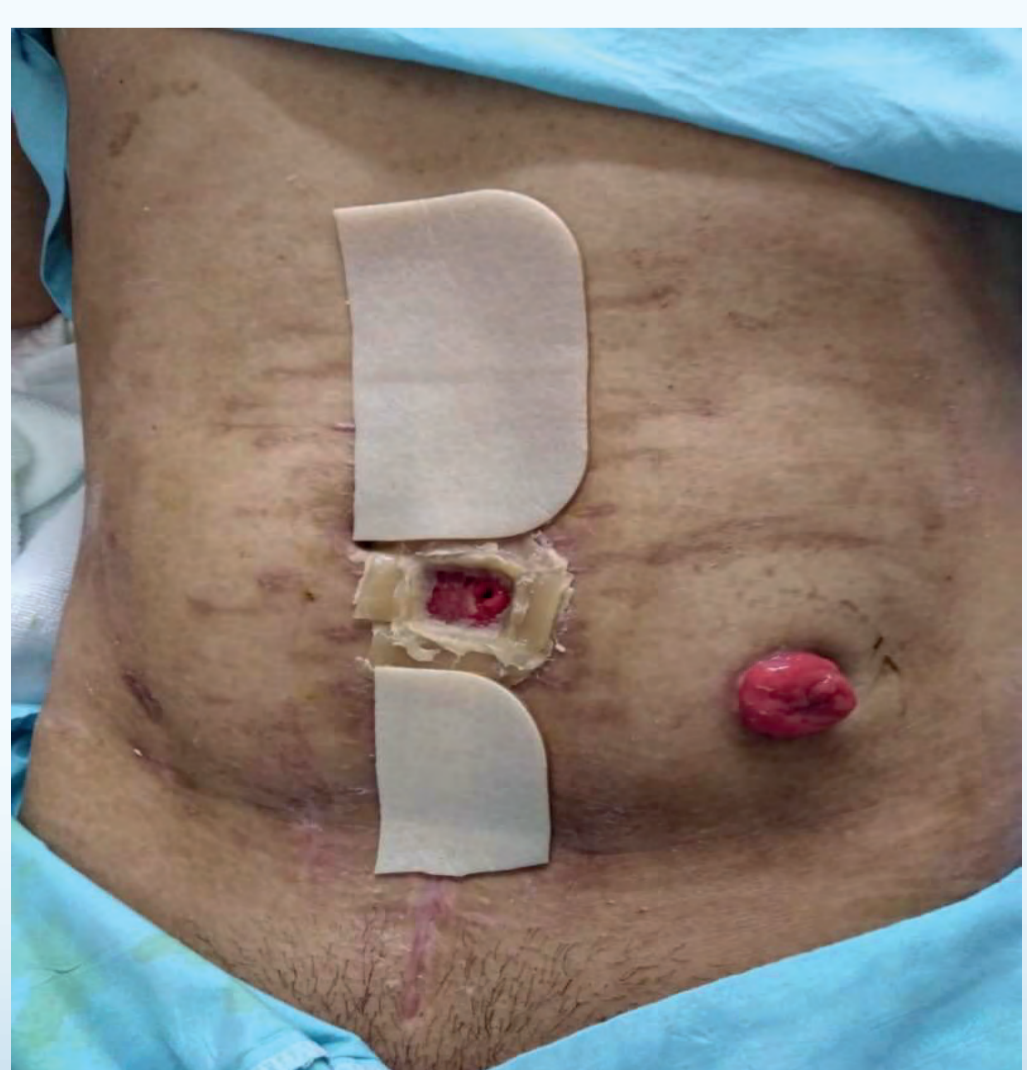


figure 2

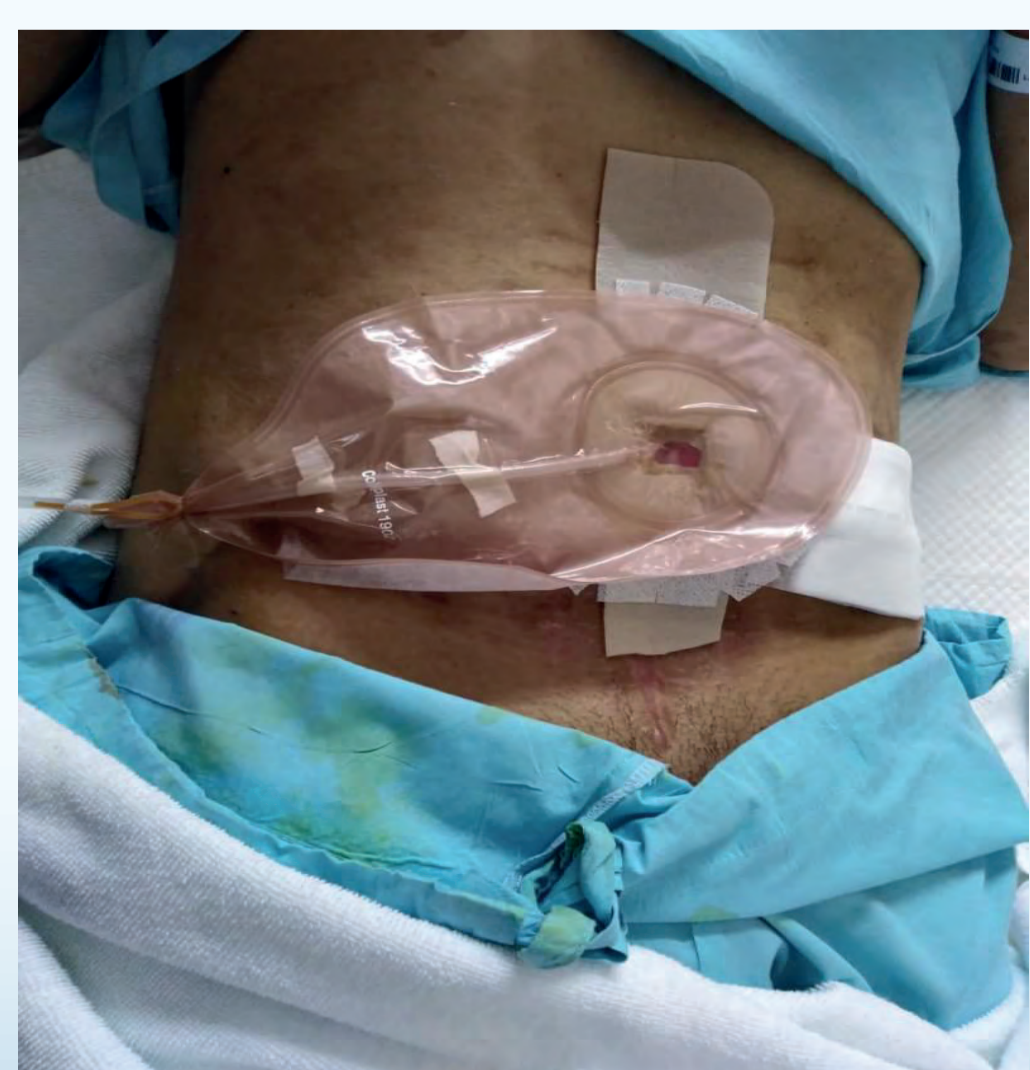

figure 3

Results

Wound size was significantly decrease in 2 weeks. (figure 4)

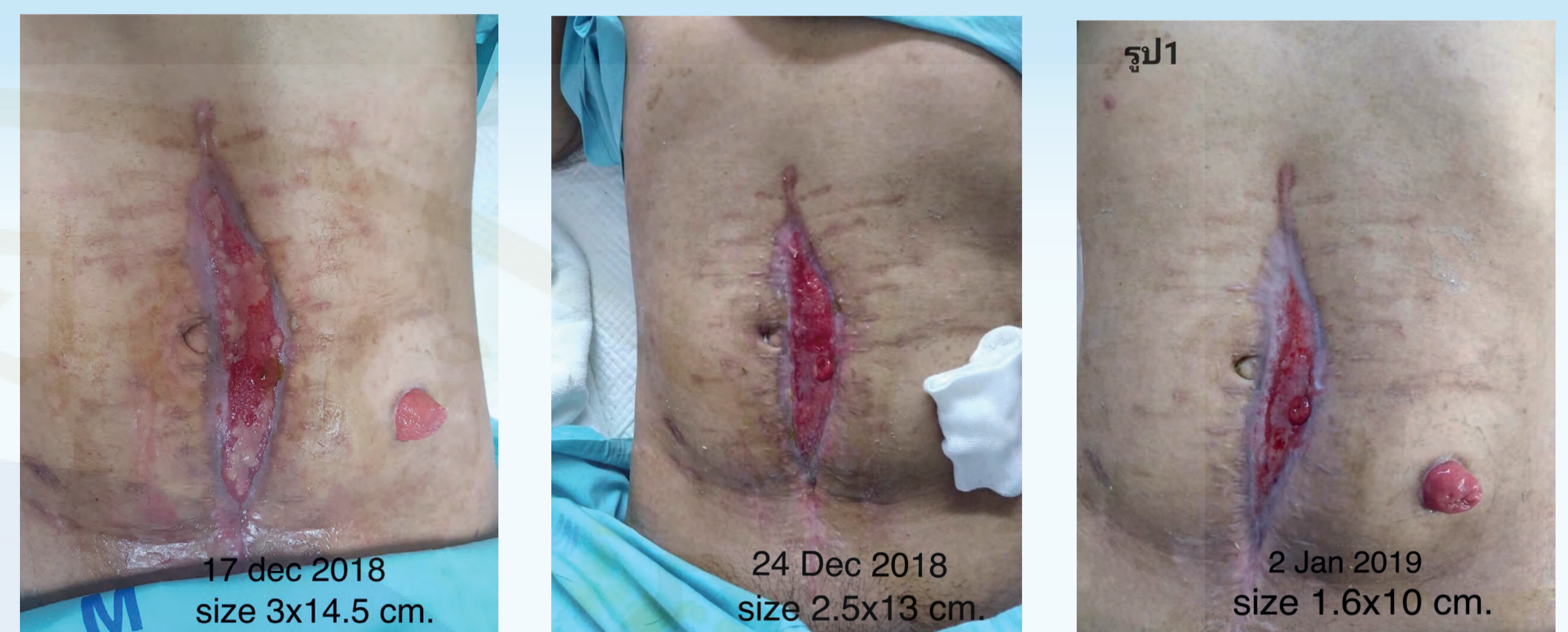

figure 4

Conclusion

Complexity management in Abdominal wound Dehiscence and EAF is super challenging. Not only the multifacets and multidisciplinary approaches but also professional judgments, experience and teamwork in which how to applicable techniques and resources on the right time, is the state of art and sciences.

Reference

- Chu, W., & Hsu, L. L. (2011). Developing practical knowledge content of emergency nursing professionals. *The Journal of Nursing Research*, 19(2), 112-118. doi: 10.1097/JNR.0b013 e31821aa0eb
- Hahler, B. (2006). Surgical wound dehiscence: *Medsurg nursing*, 15(5), 296-300

