

## Background:

Medical Devices Related Pressure Ulcer was found one third of all hospital acquired pressure ulcers<sup>1</sup>. Once a patient intubated, to maintenance of the endotracheal tube (ETT) placement is essential. When the ETT is not secured effectively, the tube may slippage which is a major factor in causing airway trauma<sup>2</sup>. However we found the endotracheal tube fixation by rope tie across the patient ears that cause pressure ulcer. The development of pressure ulcers secondary to medical devices is multifactorial. There may be direct pressure from the device or the fixation tape. In addition, the microclimate with high moisture, particularly within skin folds<sup>3</sup>.

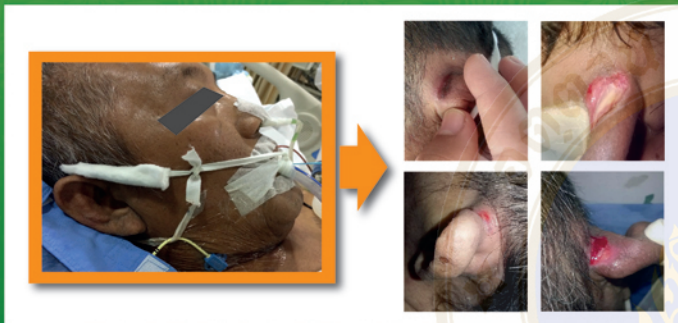


Figure 1 The traditional fixation method and pressure ulcers after fixation

## Objective:

Prevention of medical device related pressure ulcers.

## Methodology

We used an algorithm for Medical Devices Related Pressure ulcer prevention; assessment need of fixation tie, inspection of skin for pressure damage, keep skin dry and clean, consider application of protective dressing to reduce shear, friction and pressure as well as educate staff and document implementation.

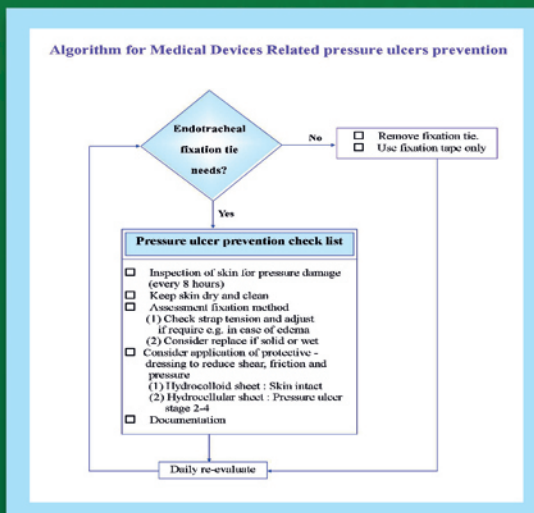


Figure 2 Algorithm for Medical Devices Related Pressure Ulcer Prevention.




Figure 3 Preparation the sheet for pressure ulcer prevention

## Result

Algorithm that could protect the patient from endotracheal tube fixation tie related pressure ulcers.

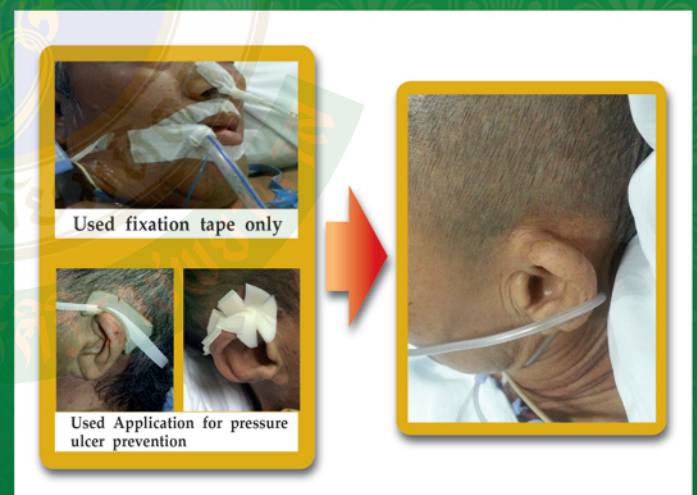


Figure 4 No pressure ulcer from endotracheal tube fixation tie after use algorithm

## Reference.

- Black J, Cuddigan J, Walko M, Didier L, Lander M, Kelpel M. Medical device related pressure ulcers in hospitalised patients. *International Wound Journal* 2010;7(5):358-65.
- Mohammed HM, Hassan MS. Endotracheal tube securements: Effectiveness of three techniques among orally intubated patients. *The Egyptian Society of Chest Diseases and Tuberculosis*. 2015;64:183-96.
- Glasgow D, S.Millen, Nzewi OC, B.Varadarajan. Device-related atypical pressure ulcer after cardiac surgery. *Journal of wound care* 2014;23(8):383-7.